



Complicated Pneumonia: Important incidental finding

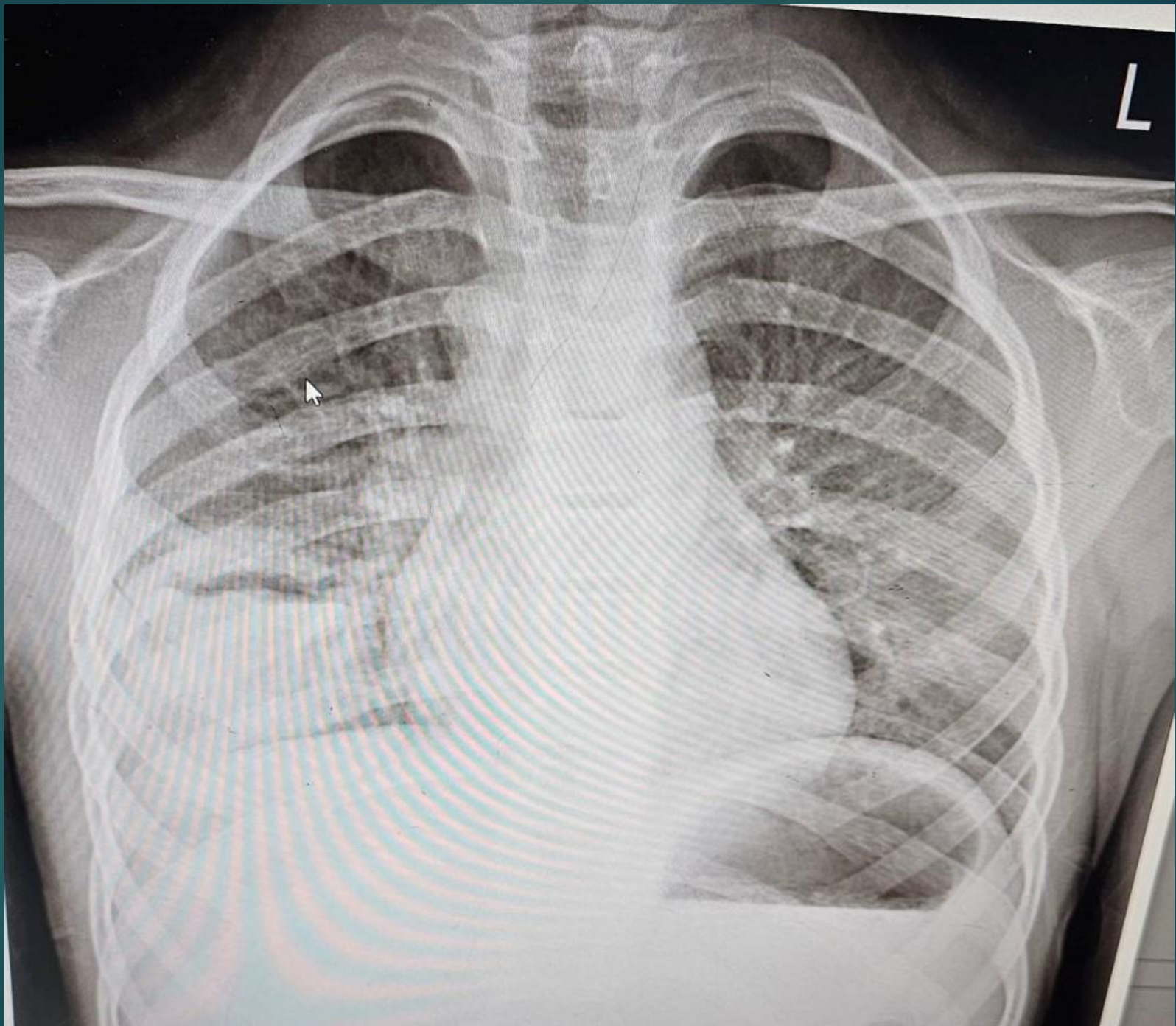
BY: SOMAYEH NAMJOO
PEDIATRICIAN

Case presentation:

- ▶ A 7 y/o girl with cc of fever and productive cough since 1 wk PTA without response to PO AB therapy.
- ▶ PMH: Repeated time common cold with prolonged cough during the last 3 months

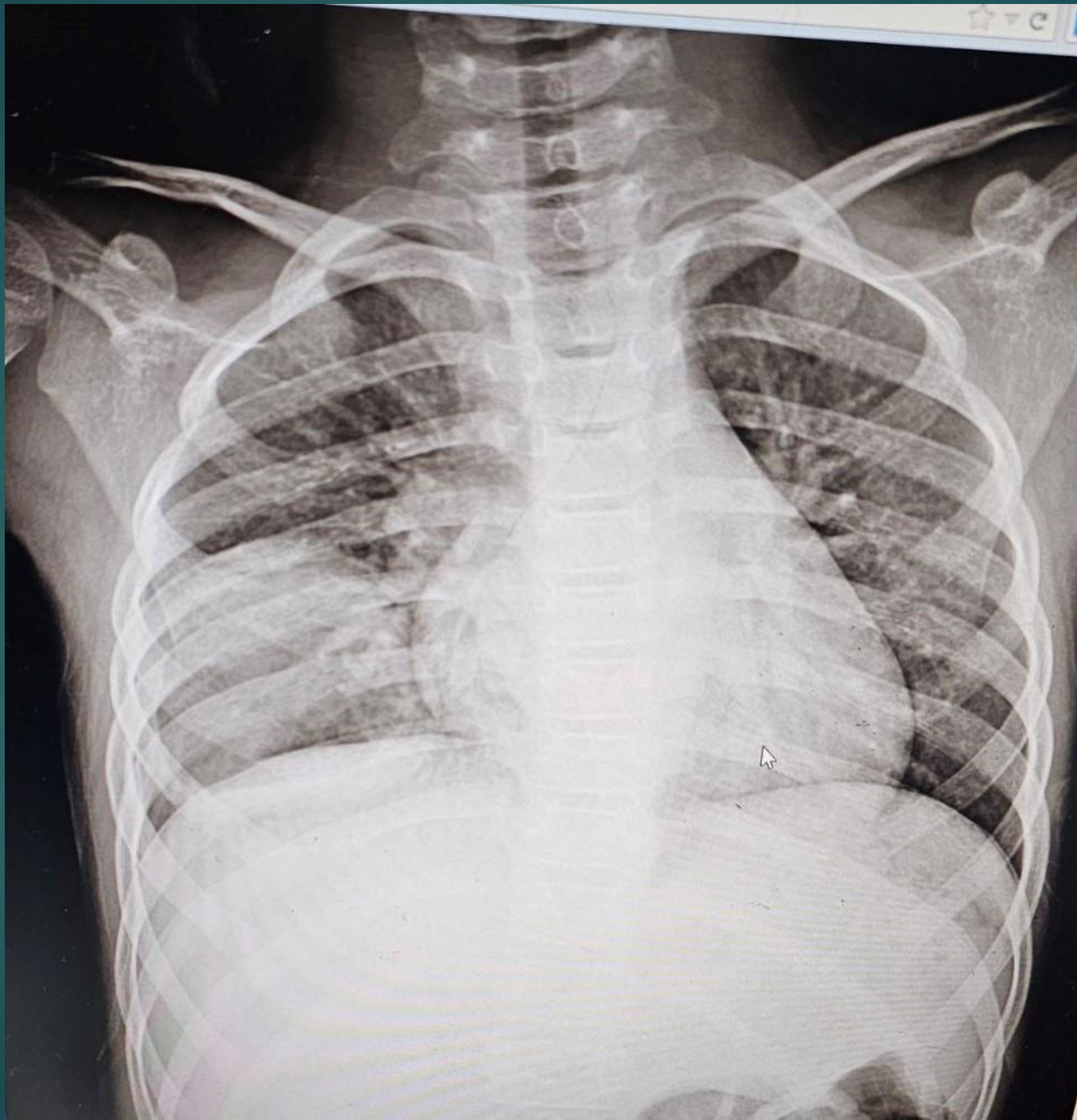
P/E:

- ▶ Well nourished, well developed
- ▶ 19 Kg
- ▶ T = 38 RR=40 HR=120
- ▶ Lung : wheezing



Lab data

- ▶ WBC = 14200 neut= 40 lym=38 mon=3
 eos=19
- ▶ Hb = 11.8
- ▶ Plt = 550
- ▶ ESR = 44
- ▶ CRP = 33
- ▶ SGOT = 47
- ▶ SGPT = 32



HRCT



